

# Preventing and Treating Adverse Events of Injectable Fillers: Evidence-Based Recommendations From the American Society for Dermatologic Surgery Multidisciplinary Task Force

Derek H. Jones, MD,\* Rebecca Fitzgerald, MD,† Sue Ellen Cox, MD,‡ Kimberly Butterwick, MD,§ M. Hassan Murad, MD,|| Shannon Humphrey, MD,¶ Jean Carruthers, MD,\*\* Steven H. Dayan, MD,†† Lisa Donofrio, MD,‡‡ Nowell Solish, MD,§§ G. Jackie Yee, MD,|||| and Murad Alam, MD¶¶¶

All injectable fillers may be associated with common injection site reactions such as redness, swelling, bruising, and tenderness, which usually resolve within 1 to 2 weeks. Rare but more serious adverse events from injectable fillers include vascular occlusion leading to skin necrosis or blindness, inflammatory events, and nodule formation, among others.<sup>1</sup> Although rare, they are likely underreported and increasing in frequency as the popularity of injectable fillers grows. Such adverse events can be distressing to both patient and physician and present therapeutic and potential legal challenges.<sup>2</sup> The American Society for Dermatologic Surgery (ASDS) has determined that the topic of preventing and treating these adverse events of injectable fillers requires the development of evidence-based clinical practice guidelines to support decision-making in daily practice.

From the \*Skin Care and Laser Physicians of Beverly Hills, Los Angeles, California; †Private Practice, Los Angeles, California; ‡Aesthetic Solutions, Assoc Clinical Faculty, UNC Department of Dermatology, Consulting Associate, Duke University Department Dermatology, Chapel Hill, North Carolina; §Cosmetic Laser Dermatology, San Diego, California; ||Evidence-based Practice Center, Mayo Clinic, Rochester, Minnesota; ¶Department of Dermatology and Skin Science, University of British Columbia, Vancouver, Canada; \*\*Department of Ophthalmology and Visual Sciences, University of British Columbia, Vancouver, Canada; ††Denova Research, Clinical Assistant Professor, University of Illinois, Chicago, Illinois; ‡‡Department of Dermatology, Yale University School of Medicine, New Haven, Connecticut; §§Department of Dermatology, University of Toronto, Toronto, Canada; |||Baker Plastic Surgery, Miami, Florida; ¶¶Departments of Dermatology, Otolaryngology, and Surgery, Northwestern University, Chicago, Illinois

D. H. Jones is an Investigator or Consultant for Allergan, Galderma, Merz and Revance. R. Fitzgerald is a Consultant for Allergan, Galderma, and Revance, and a Trainer for Galderma. S. E. Cox is Investigator and/or Consultant for Allergan, Croma, Evolus, Galderma, Merz and Revance. K. Butterwick is an Investigator or Consultant for Allergan, Galderma, Merz, Sinclair, Suneva, Histogen, Revance, and Evolus. M. H. Murad is a guideline methodologist with partial funding from ASDS to perform this work. S. Humphrey is a Consultant/Investigator/Speaker for Allergan, Galderma, and Revance, a Consultant/Speaker for Merz and L'Oreal, a Consultant for Sinclair Pharma, and an Investigator for Evolus. J. Carruthers is a Consultant and Investigator with Allergan, Alphaeon, Bonti, and Revance, and receives Royalties from Elsevier and UpToDate. S. Dayan is an Investigator or Consultant for Allergan, Galderma, Merz and Revance. L. Donofrio is a Consultant or Investigator for Canfield Scientific, Galderma, Allergan, and Revance. N. Solish is an Investigator or Consultant for Allergan, Galderma, Merz, Croma, and Revance. G.J. Yee is a Consultant for Allergan, Galderma, Revance, and Endo Aesthetics. The remaining author has indicated no significant interest with commercial supporters.

Address correspondence and reprint requests to: Derek H. Jones, MD, Skin Care and Laser Physicians of Beverly Hills, 9201 W. Sunset Boulevard, Suite 602, Los Angeles, CA 90069, or e-mail: derekjonesmd@gmail.com  
http://dx.doi.org/10.1097/DSS.0000000000002921

## Methods

American Society for Dermatologic Surgery convened a multidisciplinary task force that consisted of ASDS member physician specialists (8 board-certified in dermatology, 2 in plastic and reconstructive surgery, and 1 in oculoplastic surgery), 2 patient representatives, and a methodologist. The committee task force identified a priori 6 critical questions and commissioned the Mayo Clinic Evidence-based Practice Center to conduct systematic reviews to summarize the relevant evidence. These reviews are published separately.<sup>3</sup> The committee used the GRADE approach (Grading of Recommendations, Assessment, Development and Evaluation), which rates the certainty of evidence as high, moderate, low, or very low. Randomized trials start with a high certainty rating that can be lowered based on various factors and observational studies start with a low certainty rating that can be lowered or raised based on various factors.<sup>4</sup> The GRADE approach leads to 2 types of recommendations: (1) strong recommendations (most compelling, to be applied in most situations with minimal variation) that are denoted by the term “recommend,” and (2) conditional recommendations (variation in care is acceptable based on the context and patient’s values) that are denoted by the term “suggest.” The determination of the strength of recommendation is based on the certainty of evidence, balance of benefits and harms, patient’s values, resources, acceptability, and feasibility.<sup>4</sup>

## Prevention of Vascular Occlusion, Blindness, and Stroke

### Background

Accidental injection of filler into facial arteries can cause filler embolization and vascular occlusion, leading to tissue ischemia, necrosis, visual abnormalities, blindness, and stroke. Knowledge of vascular anatomy is essential for all filler injectors. Intravascular injection is possible at any injection location on the face, but certain locations carry a higher risk.

### Recommendations

Although there is no absolutely risk-free injection protocol, ASDS Task Force recommends the following strategies to reduce the risk of vascular occlusion with injectable fillers (Strong recommendation, Moderate certainty evidence):

- (1) Have a thorough knowledge of facial anatomy, blood vessels, and their cutaneous landmarks. Be aware that vascular variability may exist.
- (2) Be aware of higher risk locations for blindness including the glabella, medial brow, nose, forehead, superior nasolabial fold, and medial tear trough
- (3) Do not inject deep on preperiosteal planes in areas where arteries are located on bone, including the medial brow and glabella (supratrochlear and supraorbital arteries), medial canthus/tear trough (angular artery), medial cheek (infraorbital artery), and the antegonial notch of the jawline (facial artery)
- (4) Strongly consider using a 25G blunt-tipped cannula or larger where possible
- (5) Inject slowly with low plunger pressure, using small volumes with each pass, while keeping the cannula or needle moving
- (6) Obtain pretreatment informed consent about the rare possibility of intravascular injection, tissue necrosis, blindness, stroke, and the emergent use of hyaluronidase.

### Evidence and Rationale

The commissioned systematic review<sup>3</sup> included 3 comparative nonrandomized large studies and 18 noncomparative case series that fulfilled the specific inclusion criteria (a total of 7,318,824 patients who received mostly hyaluronic acid (HA) [84%] followed by calcium hydroxylapatite [10%]). The review focused on identifying risk factors such as the type and dose of the filler and injection technique.

From an anatomic perspective, the facial artery is a branch of the external carotid artery that crosses the jawline periosteally at the antegonial notch (just anterior to the anterior border of the masseter), and runs a deep, tortuous course from the lower lateral cheek to nasolabial fold, giving off branches to the inferior and superior labial arteries along the way, and becoming the angular artery near the superior border of the nasolabial fold (Figure 1). The angular artery then runs more superficially in a variety of patterns along the medial cheek and lateral nose<sup>5</sup> and then converges in an anastomotic intersection with 4 arteries: distal ophthalmic artery (with connections to the retinal and cerebral vasculature), supratrochlear and supraorbital arteries (branches of the distal ophthalmic artery, which cross periosteally over the supraorbital ridge beneath the medial brows and glabella and run superiorly through the forehead), and dorsal nasal artery along the nose. In order of risk, the nose, glabella, forehead, superior nasolabial fold, and medial cheek are considered high-risk zones for vascular occlusion and blindness,<sup>6</sup> although severe occlusion can occur at any injection location on the face, including the lips<sup>7</sup> (Figure 2A,B).

Blindness or visual compromise may very rarely occur if one of the above high-risk vessels is accidentally cannulated and retrograde flow of filler occurs through the ophthalmic artery with embolization into the retinal artery. The most common areas of injection leading to blindness are the nose, glabella, forehead, and nasolabial folds.<sup>6</sup>

The ophthalmic artery is a branch of the internal carotid artery, which supplies the cerebral vasculature. End arteries of the ophthalmic artery may anastomose with branches of the external carotid artery such as the superficial temporal artery. Retrograde flow to the cerebral vasculature from

such connections between the external and internal carotid artery system can rarely result in stroke and neurologic compromise.<sup>6</sup>

Needles and blunt-tipped cannulas both can perforate vessel walls. Larger 25G blunt-tipped cannulas, compared with smaller diameter cannulas and needles, have proven less likely to perforate vessels in cadaver models.<sup>8</sup> Surveys also suggest that intravascular occlusion is more common with needles.<sup>7</sup>

Injecting small volumes slowly and gently is recommended, because large volumes injected under high pressure may create more extensive occlusion in the case of accidental arterial injection. In addition, keeping the cannula or needle moving may reduce the likelihood of prolonged intravascular injection.

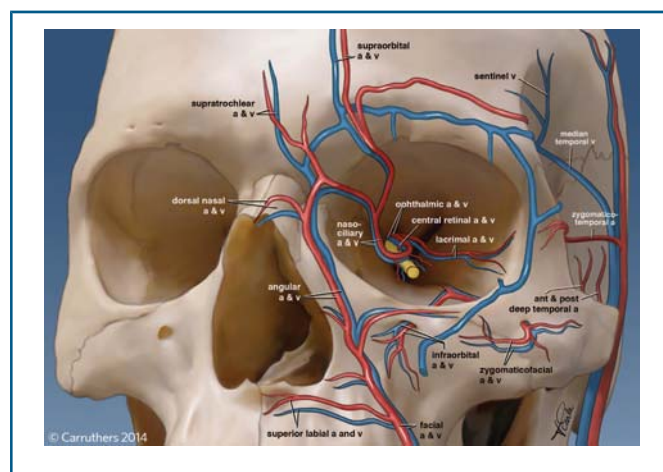
Retraction of the plunger on a syringe of HA filler (reflux test) is recommended before injection. Blood upon reflux indicates possible intravascular placement, indicating to immediately stop and reposition.<sup>9,10</sup> A negative reflux test does not definitively exclude intravascular placement.

### Certainty in Evidence and Strength of Recommendation

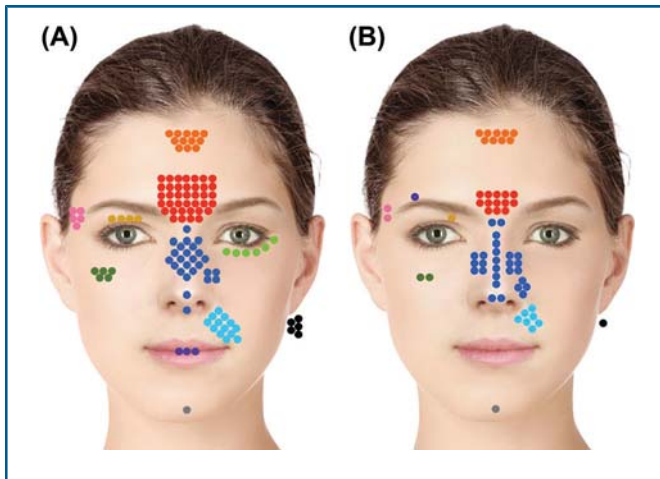
The current recommendation depends on observational studies and basic anatomic and surgical principles in which we have higher certainty and can be considered best practice statements. Therefore, an overall moderate certainty rating was judged to be appropriate across the various strategies to reduce the risk of vascular occlusion with injectable fillers. This recommendation is strong and compelling because deviations from these surgical principles can lead to important complications. The panel, which included patient representatives, considered patient's values that emphasize avoidance of complications and other factors such as feasibility and acceptability of these preventive measures.

### Implementation Techniques

Facial vascular anatomy should be studied in depth by all injectors. Cadaveric dissection courses and injection-related



**Figure 1.** Vascular anatomy of the periocular region. Reproduced with permission from Carruthers and colleagues.<sup>30</sup>



**Figure 2.** (A) Location of injection for each case of blindness from filler in 98 cases reviewed by Belezny and colleagues.<sup>23</sup> Reproduced with permission. (B) Location of injection for each case of blindness from filler in 48 cases in an updated review by Belezny and colleagues.<sup>6</sup> The black dots represent cases in which the location was not specified and listed as “face.” Reproduced with permission.

vascular literature are recommended to learn the location and depth of major facial vessels.<sup>11</sup>

Although there is no completely risk-free injection protocol, the following are suggested as safer regional injection approaches:

### **Glabella, Nose, and Forehead**

All 3 areas are high risk and should be approached with great caution only by the most experienced physician injectors. Do not inject deeply or on periosteum with needles or cannulas in the glabella, where supratrochlear and supraorbital arteries reside. Very experienced physicians may consider treating glabellar rhytides with superficial intradermal injections using small needles. The vasculature is variable, however, and may lie in a more superficial position.<sup>12,13</sup> Forehead reflation is considered safer with cannulas in the preperiosteal, subgaleal plane, 2 cm or more superior to the brow where the supratrochlear and supraorbital vessels run more superficially within the frontalis muscle.<sup>14</sup> Major vessels in the forehead run cephalad to caudal, and injections should be considered in the horizontal plane to avoid direct cannulization. Nasal injections represent the highest risk for blindness due to injection into the dorsal nasal artery. Cadaveric studies suggest that the safer plane of injection to the dorsal nose is preperiosteal or preperichondrial.<sup>15</sup> However, the vasculature is variable, and the dorsal nasal artery may lie on the periosteum in the midline.<sup>16</sup>

### **Temple**

For reflation of the temple, the injection is deep to the superficial temporal vessels, on periosteum with a needle. The suggested safe zone is 1 cm up from the superior orbital rim, and 1 cm lateral to the temporal fusion line, and over

2.5 cm above the zygomatic arch to avoid the middle temporal vein.<sup>17,18</sup>

### **Cheeks and Nasolabial Fold**

On the lateral cheek, periosteal injection with needle or cannula on the zygomatic prominence is generally considered safe, although the zygomaticofacial artery lies on periosteum, and a reflux test may be positive.<sup>10</sup> However, the medial cheek, medial to the midpupillary line, contains vessels that run periosteally (infraorbital vessels) and subcutaneously (variations of the angular artery) that are high risk. The facial artery runs deep in the submalar cheek, becoming the subcutaneous angular artery around the nasolabial fold. Although both needles and cannulas are FDA-approved in the medial cheek, submalar cheeks, and nasolabial folds, a 25G cannula or larger may be safer as cadaveric studies and reflux studies show the ability of needles to easily enter high-risk vessels in these areas.<sup>7,8,10</sup>

### **Lips**

The labial arteries run deep to the wet dry line on the lips within the mucosa of the orbicularis oris. Injections should be superficial. The course of this artery has been recently reviewed.<sup>19</sup>

### **Chin and Jawline**

Although periosteal injections appear safer on the inferior midline mandible to create chin projection and on the angle of the mandible to increase jaw width, care must be taken not to inject in a periosteal location along the mandibular ramus, just anterior to the anterior border of the masseter where the facial artery runs.<sup>11</sup>

### **Future Considerations**

Cadaveric and imaging studies continue to enhance our knowledge of facial vascular anatomy.<sup>11</sup> Health care professionals should continue to study facial vascular anatomy in depth for the life of their career, with the understanding that it is invariably variable. Although there is no absolutely safe injection protocol, safer injection strategies may mitigate disastrous outcomes. The recent use of ultrasound in revealing vasculature may show promise.<sup>20</sup>

## **Treatment of Filler-Related Vascular Occlusion With Blindness**

### **Background**

Although the earliest reports of injection-related visual compromise (IRVC) were from autologous fat,<sup>21-23</sup> more recent reviews reveal an increase in HA-related cases.<sup>6,24-27</sup> This likely reflects the exponential increase in worldwide HA filler use.<sup>28</sup> Almost 200 unique cases of IRVC have been reported in the literature: 49% HA, 29% fat, and 22% from other fillers.<sup>23-27,29</sup> Although IRVC is rare, it is widely believed to be underreported.

## Recommendations

The ASDS Task Force suggests the following strategies to reduce the risk of IRVC (conditional recommendation, low certainty evidence):

- (1) Obtain informed consent from the patient regarding the rare possibility of IRVC, which can have life-altering consequences.
- (2) Develop and post an IVRC protocol, review it with team members, and always have ample hyaluronidase on hand.
- (3) Stop injecting at first sign of visual compromise, which usually occurs during or immediately after injection and is most often unilateral. Half of the patients show skin involvement, ophthalmoplegia, or ptosis, of which most resolve. Headache, nausea, and vomiting may or may not be present.
- (4) Conduct evaluation of immediate postevent visual status BEFORE any intervention. The importance of this cannot be overstated.
  - Document visual acuity in each eye separately and note in chart:
    - a. Ability to read letters (Snellen chart, near card, or magazine print)
    - b. Ability to count fingers
    - c. Ability to perceive hand motion
    - d. Light perception (LP)
    - e. No LP (NLP)
  - Extraocular muscle function
  - Pupillary response to light
  - Photograph face in primary position
- (5) Keep patient informed of evolving events, notify family member, and accompany both through entire process.
- (6) In patients with signs or symptoms (s/s) of central nervous system (CNS) involvement, contact your local hospital's emergency stroke service and call 911 for immediate transport to the emergency room. In the absence of s/s, evaluate and image the patient to rule out CNS involvement once the ocular event has been addressed.
- (7) Time is of the essence. Immediately contact an eye expert who is familiar with this risk and its management. A preexisting relationship with an oculoplastic surgeon, ophthalmologist, and/or retina specialist can avoid unnecessary delays.
- (8) Hyaluronidase injections are quick, safe, and easily done at the bedside, and should be considered immediately. Inject >150 units hyaluronidase into the treated area, all areas of skin ischemia, and along the path of arteries leading to the eye. Similar doses can be injected adjacent to and in the supraorbital and supratrochlear foramina. Repeat in quick succession as needed. Retrobulbar (RBH) and peribulbar (PBH) injections may be beneficial, but this remains controversial at this time.
- (9) Conservative measures that are quick, safe, and easily done at the bedside can be done simultaneously.
  - Breathing into a paper bag (carbogen)
  - Ocular massage. Manually press the globe firmly for cycles of 5 to 15 seconds intercalated by rapid release (rapid reperfusion may dislodge embolus), repeat for a total length of 5 minutes, rest (a few minutes), then repeat. This may be continued over hours.
  - Topical Timolol and 500 mg oral acetazolamide to decrease intraocular pressure can be easily administered.
- (10) Inform your indemnity malpractice carrier about the event as reporting requirements for coverage vary geographically.

Keep detailed notes of events, interventions, and timing, and all interactions with patient, family, specialists, and facilities. Inform the product manufacturer of the incident for FDA reporting.

## Evidence and Rationale

The commissioned systematic review<sup>3</sup> included 8 case series that fulfilled the specific inclusion criteria (a total of 96 patients who were treated for IRVC). Hyaluronidase injections were the main treatment used in the studies (retrobulbar, skin, and intralesional injections). Other treatments reported in these series were glucocorticoids, mechanical recanalization, urokinase injections, ocular massage, antiplatelet therapy, intraocular pressure lowering drugs and procedures, nitroglycerin, anticoagulants, and hyperbaric oxygen therapy. There were no comparative studies to provide reliable efficacy estimates for the various interventions. On the final evaluation, only 19% of the patients reported some degree of recovery from IRVC events.

From anatomical and physiologic standpoints, the leading hypothesis of HA IRVC pathogenesis involves inadvertent intra-arterial injection and retrograde flow of filler into the arterial supply of the eye (Figure 1).<sup>21,23</sup>

The treatment goal is to recanalize the occluded vessel(s) and reperfuse the tissue. IRVC is an ophthalmologic emergency. The most cited window of time for reperfusion is 90 minutes.<sup>31</sup> However, newer literature suggests it may be as little as 10 to 15 minutes, emphasizing the need for immediate recognition and a streamlined protocol.<sup>32</sup> The extent of visual compromise should be evaluated and documented before any intervention. The patient must be kept informed about the details of your treatment plan. Twenty percent of patients have CNS involvement necessitating emergent transfer to the hospital if any s/s are present.<sup>6,23</sup> A pre-existing relationship with an eye specialist familiar with this condition is an invaluable asset. British Eye Emergency Care Society survey data revealed that most of their specialist practitioners did not have local management guidelines for this complication (88%) nor were they aware of where to seek guidance to manage the complication (75%).<sup>33</sup> Plan accordingly and choose carefully. Litigation analysis commonly revealed deficiencies of informed consent.<sup>2</sup>

There is no current evidence-based standard of care for treating iatrogenic retinal embolism from HA filler. Kapoor's review of 44 cases from 2004 to 2019 using Preferred Reporting Items for Systematic Reviews and Meta-Analyses guidelines was rated as level 3 evidence by the publishing journal.<sup>34</sup> Combined with a newly published case series of 24 patients from China,<sup>27</sup> these data comprise 70% (68/96) of the reported HA IRVC cases. Commonalities from these sources show the vast majority are from Asia, seen in young female patients, occur immediately after injection, and are unilateral. About half show skin involvement and/or ophthalmoplegia, from which most resolve.<sup>34-36</sup> Most cases involved injections in the nose,

glabella, and forehead. Temple, periorbital, and cheek accounted for the rest (Figure 2A,B).

Notably, cases involving the lower face (lip, chin, jawline) showed these patients were also injected in higher risk anatomic sites at the same session. No cases of HA IRVC were reported from the lower face when these areas were injected in isolation.<sup>23,26,34</sup>

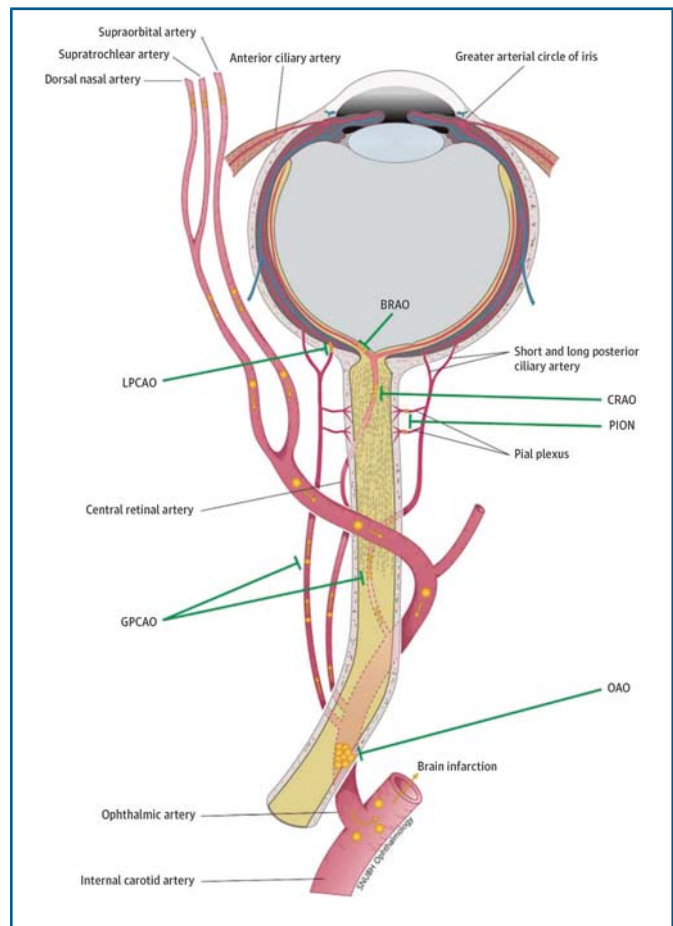
Degree of vision loss predicts location of the embolus, which may be the most important prognostic factor. Partial vision loss after HA filler has a better prognosis than complete vision loss (Figure 3).<sup>21,26,34</sup>

Presentation with complete vision loss (NLP) is most often associated with ophthalmic artery occlusion (OAO) or central retinal artery occlusion (CRAO), and most do not recover.<sup>21-23,34,37,38</sup> Presentation with partial vision loss (blurry vision to diminished LP) is less commonly associated with OAO/CRAO, and more often includes more distal branches of both the posterior ciliary arteries or the central retinal artery, likely due to smaller emboli. Branch retinal artery occlusion (BRAO) has the most favorable prognosis.<sup>26</sup> Eighty percent of fat emboli present as complete vision loss, whereas 50% of HA present as partial vision loss, accounting for its better prognosis.<sup>21,23,34</sup>

All fully and partially recovered patients received some form of treatment.<sup>6,34</sup> The improvement rate was 42% (20/47) in those treated with hyaluronidase versus 33% (7/21) in those that did not receive hyaluronidase. Hyaluronidase degrades HA, affording a potential opportunity for vision rescue. The short therapeutic window and the ability to get the enzyme to the embolus are the challenges. Therefore, timing, dose, route of administration, secondary thrombosis, and perhaps the type of HA may all play a role. Kapoor found the nose, glabella, and forehead accounted for 85% of the cases.<sup>34</sup> These areas are supplied by the supraorbital, supratrochlear, and dorsal nasal arteries, which are terminal branches of the ophthalmic artery and therefore provide a direct path to the ocular circulation.<sup>21,26,34</sup> Because vascularity is often variable and the location of the embolus (or emboli) is unknown, it may be prudent to flood this entire area and the supraorbital and supratrochlear foramina with hyaluronidase.<sup>39</sup> High-dose hyaluronidase injected quickly at multiple sites (subcutaneous ± Foramina ± RBH) showed the most favorable results.<sup>39-44</sup> There are 7 reports of full recovery with the use of hyaluronidase.<sup>39-44</sup> PBH/RBH injections may be beneficial, but remain controversial awaiting further safety and efficacy data.<sup>26,45,46</sup> A favorable risk/benefit ratio may exist in cases of impending blindness when performed by a trained practitioner.<sup>45</sup> Cases treated with intra-arterial thrombolysis (IAT) using thrombolytics, hyaluronidase, or both, have heretofore reported disappointing results.<sup>21,38,47</sup> However, Zhang recently reported improvement in 10/24 cases (42%) using IAT with hyaluronidase ± urokinase, despite presentation with NLP/LP and delayed treatment.<sup>29</sup>

Traditional treatment for ocular occlusions not related to HA are aimed at lowering intraocular pressure with Timolol drops, acetazolamide, IV mannitol, or digital massage, dilating the retinal arteries (carbogen), decreasing edema

(prednisone), and inhibiting thrombosis (aspirin).<sup>21-23</sup> Specialist treatments include anterior chamber paracentesis, direct intra-arterial or IV injection of hyaluronidase ±



**Figure 3.** Schematic drawing of the ophthalmic artery, its branches, and possible obstruction points. Injected filler material (yellow droplet) is presumed to access the ophthalmic artery retrogradely via the supratrochlear, supraorbital, or dorsal nasal artery. Ophthalmic artery occlusion (OAO) is likely caused by complete proximal ophthalmic artery obstruction by a large filler bolus that migrated backward from the high injection pressure. It may also be that small particles migrated back to the central retinal artery and posterior ciliary artery origins and dispersed anterogradely into each branch as injection pressure decreased. This would cause a diffuse obstruction. Generalized posterior ciliary artery occlusion (GPCAO) or central retinal artery occlusion (CRAO) may occur depending on the extent of central retinal artery or posterior ciliary artery obstruction. When only the medial short posterior ciliary artery is involved, localized posterior ciliary artery occlusion (LPCAO) involving only the nasal choroid occurs. When only a branch of the central retinal artery is occluded, a branch retinal artery occlusion (BRAO) occurs. The mechanism of posterior ischemic optic neuropathy (PION) remains uncertain. The pial vascular plexus supplies blood to the intraorbital posterior optic nerve, and some vessels responsible for the pial plexus, which usually arise directly from the ophthalmic artery, may also be involved in these cases. Last, some particles may have accessed the internal carotid artery, causing a brain infarction. Reproduced with permission from Park and colleagues.<sup>21</sup>

urokinase for which isolated cases of improvement have been reported.<sup>6,23</sup> There are 2 reports of full recovery without the use of hyaluronidase. One was a BRAO who received 500 mg acetazolamide immediately; the other presented with a visual acuity of 20/20 and ophthalmoplegia who worsened to 20/200 with a field defect in 24 hours, then recovered after 14 days of conservative therapy.<sup>48,49</sup>

### **Certainty in Evidence and Strength of Recommendation**

The current recommendation depends on uncontrolled observational studies and extrapolation from indirect evidence, case reports, and the panel's clinical experience. Therefore, the overall certainty rating was judged to be low. This recommendation is conditional. The panel, which included patient representatives, considered patient's values that emphasize avoidance of visual complications and other factors such as feasibility and acceptability of these preventive measures.

### **Implementation Techniques**

Hypersensitivity reactions to hyaluronidase are uncommon but have been reported, mostly in the ophthalmology literature (0.05%), but not in the dermatology literature.<sup>50</sup> Patients with a history of anaphylactic reactions to bee stings may be more at risk.<sup>50</sup> Urgent situations may not allow time for skin testing. Video instructions for visual acuity testing and ocular massage can be found at (See **Supplemental Digital Content 1**, video, <http://links.lww.com/DSS/A730>).

### **Future Research**

A registry to obtain the true number of cases and treatment details would be a valuable resource.<sup>51</sup> Information to further clarify the mechanism of action of this complication will guide techniques for prevention and treatment. Hyaluronidase ± thrombolytics may play a critical role in the treatment of HA IRVC, and further studies on the timing, dose, and route of administration (IAT, IV, RBH, OA injection) are needed, as is a more concentrated form of hyaluronidase to increase the dose without increasing the volume in some applications. Because this is a rare event, cadaveric and animal studies are invaluable.<sup>52-54</sup>

## **Treatment of Vascular Occlusion Without Blindness (Skin Ischemia)**

### **Background**

To reach areas that require tissue augmentation, needles or cannulas used to inject prepackaged soft tissue fillers into the deep dermis and subcutaneous tissues of the face often traverse densely vascularized areas, particularly those in the vicinity of the nose and mouth.<sup>55-57</sup> Veins or arteries may be inadvertently perforated such that filler material enters them, creating an obstruction that may impair vessel patency. It may be possible for the filler to accumulate adjacent to a vessel in sufficient quantity to cause tamponade and compromise blood flow. If not promptly

recognized<sup>58</sup> and treated, either of these events, although infrequent,<sup>59</sup> can culminate in, successively, local tissue ischemia, necrosis, eschar and tissue slough, and permanent scar.

### **Recommendations**

The ASDS task force recommends the strategies below for treatment of vascular occlusion (strong recommendation, moderate certainty evidence):

- (1) During a patient filler injection, when vascular regurgitation in the syringe (i.e., "red flash") or tissue blanching in the treatment area is observed by the health care professional injector, the injection should be stopped and treatment with injectable hyaluronidase be considered.
- (2) In patients who develop vascular occlusion of the skin of the face after treatment with filler, high-dose hyaluronidase should be injected promptly into the skin at the site of occlusion and any areas of ischemia on the immediate periphery.

### **Evidence and Rationale**

The commissioned systematic review<sup>3</sup> included 8 case series that fulfilled the specific inclusion criteria (a total of 100 patients who were treated for vascular occlusion without blindness after the use of injectable fillers). Occlusive events were predominantly reported after receiving HA filler injections (97%). All of the included studies reported the use of hyaluronidase injections (including retrobulbar and skin injections) at a median time of 45 hours after developing vascular occlusion. The review did not identify any comparative studies. Across these series, 77% of the patients recovered from the vascular occlusive events (complete resolution of vascular occlusions without skin necrosis was achieved in 49% of the included cases).

A common surgical principle with supporting mechanistic evidence is that if blood enters the filler syringe when the needle tip is positioned at the point of injection and the plunger is retracted, this indicates that the needle tip is in a vessel lumen or has perforated a nearby vessel.<sup>60</sup> In this event, continuing to inject filler would increase the risk of vascular occlusion. Transient tissue blanching, or whitening, possibly in a reticulated pattern (i.e., livedoid), and lasting a few seconds or longer, has also been noted to be an indicator of vascular compromise due to filler injection. When observed, this blanch typically occurs immediately after the filler is injected. Patient-reported pain, asymmetric edema, and slow capillary refill may help confirm the diagnosis.<sup>61</sup>

Since 1971, it has been known that hyaluronidase is effective for catalyzing the disintegration of HA, the principal constituent of HA fillers. Among the FDA-approved formulations of hyaluronidase are those that are animal-derived (Hydase and Vitrase) and human recombinant (Hyalenex). Of all the measures that can be undertaken to reverse an unwanted accumulation of HA filler in or around a vessel, hyaluronidase injection is the most specific and also the only intervention supported by virtually unanimous expert consensus.<sup>62-72</sup> Hyaluronidase is believed to be effective in this context by dissipating the HA

filler both in the vessel lumen and encircling the vessel. Although there is a lack of consensus regarding the optimal dosage of hyaluronidase, which may vary based on clinical circumstances and the particular HA formulation, there is consensus that total dosage at each point in time hyaluronidase is injected should be on the order of hundreds of units.

### **Certainty in Evidence and Strength of Recommendation**

Reliance on signs such as “red flash” or tissue blanching is supported by physiologic and anatomic principles and likely reflects high certainty evidence. The certainty of evidence supporting the effectiveness of injectable hyaluronidase is of lower certainty and is based primarily on observational studies. However, the strong recommendation for its use as a treatment after a vascular occlusion has occurred is based on patient’s values that emphasize avoidance of complications and other factors such as safety, feasibility, and acceptability of using hyaluronidase.

### **Implementation Techniques**

Hyaluronidase injections are likely to be most useful in reversing a skin vascular occlusion and preventing tissue necrosis if they are delivered immediately after occlusion. In addition, since the half-life of hyaluronidase in the skin is counted in minutes, repeat injections should be considered. A recent study by Lee and colleagues<sup>63</sup> found superior results when 500 units was administered as 125 units at 15-minute intervals rather than as a single bolus. Unfortunately, vascular occlusions of the skin are often not detected at the time of injection, instead being discovered when the patient reports persistent pain, swelling, or redness 1 or 2 days later.<sup>73</sup> Because office staff may receive the relevant call from an affected patient, identification of the problem may be contingent on nurses and other office staff being educated<sup>51</sup> that such sequelae require further investigation, ideally with the patient coming to the office for a clinical examination.

Apart from hyaluronidase injections, skin massage, intralesional or systemic corticosteroids, warm compresses, and oral aspirin may be helpful in treating skin vascular occlusion. The expert panel noted that nitroglycerin may be less useful.<sup>74–76</sup> If a calcium hydroxylapatite filler is responsible for an occlusion, there is early evidence that sodium thiosulfate injection may dissipate the filler,<sup>77,78</sup> although evidence is lacking regarding its use with vascular occlusion. By 1 to 2 days after occlusion onset, necrosis may not be preventable.<sup>79,80</sup> At this point, management consists of wound care, including appropriate topical emollients and wound dressings. Antimicrobials, such as antibiotics or antivirals, may be considered if there is evidence of incipient infection in devitalized skin, and hyperbaric oxygen treatments have been attempted.<sup>81</sup> Once the site has healed, the need for scar revision is evaluated.

Reducing the risk of skin vascular occlusions may be possible. There is an emerging consensus that filler injection with cannulas,<sup>82</sup> particularly those of higher bore, may be

less likely to injure vessels than injection with needles. Slow, superficial, and low volume injections, and injections that aim upward, tenting the skin, may also reduce risk, although these common-sense strategies have not been well-studied.

### **Future Research**

Research is needed to better understand the pathophysiology of vascular skin occlusions associated with filler injections. Animal studies may be appropriate to characterize the scale and loci of anatomic disruptions, which may clarify the optimal doses of hyaluronidase needed and also provide insight into injection methods that reduce the risk of intravascular injection.

## **Reducing the Incidence of Nodules With Hyaluronic Acid Fillers**

### **Background**

Nodules can develop with injections of all iterations of HA soft tissue fillers.<sup>1,83</sup> For the purposes of these ASDS evidence-based guidelines, we define nodules as early or late onset events (late presenting more than 4 weeks post-treatment) and as either inflammatory (erythematous, edematous, tender, hot) or noninflammatory (nontender, minimal erythema). Delayed-onset adverse reactions of over 1-month duration are uncommon, but with the advent of newer fillers and increased popularity of injectable soft tissue augmentation, more reports of such events are found in the literature.<sup>83</sup> In addition, delayed nodules because of certain HA fillers manufactured with Vycross technology have been found in some reports to have a higher incidence of late-onset nodules.<sup>84–87</sup> Prevention strategies are therefore needed.

### **Recommendations**

The ASDS task force recommends active adoption of strategies to reduce the risk of inflammatory and non-inflammatory early and late nodules (strong recommendation, low certainty evidence):

- (1) Obtain a thorough history regarding active facial infection, autoimmune diseases, recent dental work, immunizations, facial trauma, and past history of permanent or non-HA fillers
- (2) Avoid injection into areas with active inflammation
- (3) Adopt aseptic technique
- (4) Use the smallest bolus possible, such as 0.1 to 0.2 mL.
- (5) Provide post-treatment patient education including delaying application of make-up, creams, lotions, tap water, ice, and avoiding manipulation of the area after the procedure
- (6) Avoid dental procedures, invasive diagnostic procedures, and surgical procedures for greater than 2 weeks either before or after filler procedures

### **Evidence and Rationale**

The commissioned systematic review<sup>3</sup> included 41 randomized controlled trials, 6 comparative observational studies, and 81 noncomparative case series that reported on a total of 6,183,147 patients who received different brands of HA filler injections for aesthetic purposes. The review also

included a separate analysis with a total of 2,537 nodules and inflammatory events related to HA injections reported to the FDA MAUDE database over a 10-year period (2007–2017). The review focused on identifying risk factors such as the type and dose of the filler and injection technique.

The overall safety profile of HA fillers is very good. Adverse events are rare based on the number of worldwide injectable procedures. Delayed-onset adverse event reactions are uncommon and consist of both cyclic and persistent areas of facial edema, erythema, tenderness and firm nodules, or indurated plaques. The underlying etiology may involve either the manufacturing process or nature of the product, host sensitivity, injection technique, or a combination of these factors. Inflammatory nodules may stem from systemic immune up-regulation, hypersensitivity, foreign body reaction, infection, sterile abscess, or biofilm.<sup>88–90</sup> Noninflammatory cold nodules may be due to inadvertent placement superficially, migration, or excessive product. Host factors include immune sensitivity, prior permanent fillers, and systemic or active infection. Some series have demonstrated an increased risk of delayed nodules after a flu virus,<sup>85</sup> after vaccinations or immunizations,<sup>91</sup> and during cold and flu season.<sup>92</sup> Regarding the type of HA, 3 separate studies indicated that Vycross technology has a 1% to 4% delayed nodule risk, which may be related to the area injected (lips, tear trough).<sup>86,87,92</sup> Although unclear, lower molecular weight oligosaccharides in Vycross may be immunogenic. Hypersensitivity has been most associated with delayed-onset nodules, but biofilms and atypical organisms have been implicated in some cases.<sup>88,89</sup> Aseptic technique is encouraged, although clinical evidence has failed to prove that one technique is better than another.<sup>91,93,94</sup> There is a lack of consensus regarding the period of time to resume make-up application and avoid tap water exposure, although most suggest a delayed period of time after the filler session.<sup>84</sup>

### **Certainty in Evidence and Strength of Recommendation**

The current recommendation depends on observational studies and basic anatomic and surgical principles in which we have higher certainty and can be considered best practice statements. The evidence supporting strategies and interventions to reduce the risk of nodules after injection is however of low certainty. The panel, which included patient representatives, considered patient's values that emphasize avoidance of nodules and other factors such as feasibility and acceptability of these preventive measures.

### **Implementation Techniques**

A thorough patient history is essential. Aseptic technique is an important preventative factor. Patients must have a clean, make-up free face before injections. Alcohol alone may not be sufficient. Antiseptic cleansers such as chloroxylenol, benzalkonium chloride, hypochlorous acid, or povidone iodine should be considered. Avoid touching the

cannula during treatment, and change needles frequently. Larger injection quantities may contribute to an increased level of risk.<sup>92</sup> Specific types of fillers such as HAs with Vycross technology have been associated with increased risk. Patients should be advised to avoid potential triggering factors (dental procedures, vaccinations, manipulation) for a period of 2 weeks or longer following HA filler injections.

### **Future Research**

Research is needed to better understand the differences in injectable fillers, specifically why certain crosslinking technology such as Vycross with both high and low molecular weight particles seems to be more immunogenic. More evidence-based data on prevention, aseptic technique, and treatment is necessary. In addition, a central repository to collect these types of complications is crucial.

## **Treatment of Nodules and Inflammatory Events From Hyaluronic Acid Fillers**

### **Background**

Hyaluronic acid fillers have become the most versatile and widely used subset of volumizing fillers worldwide. Inflammatory and noninflammatory nodules due to HA filler injections are uncommon, but there are a number of reports of nodule formation due to all HA fillers.<sup>1</sup> Early nodules (developing <4 weeks after implantation) may be common treatment responses that usually resolve, or related to injection technique (too superficial, excessive amount, incorrect anatomical area) and are reversible with hyaluronidase. Late-onset nodules (developing >4 weeks after implantation) have been increasingly reported in the past 5 years,<sup>85,86,92</sup> and their diagnoses and management are often challenging.

### **Recommendations**

The ASDS task force suggests the following measures to manage inflammatory and noninflammatory early and late nodules (conditional recommendation, low certainty evidence):

- (1) Differentiate between noninflammatory (firm, nontender, no erythema) and inflammatory (erythematous, edematous, tender).
- (2) Noninflammatory nodules caused by overcorrection or superficial placement that are persistent and bothersome may be treated with intralesional hyaluronidase
- (3) For inflammatory nodules, rule out possible infection by history and examination (warmth, drainage, fluctuance, severe induration, tenderness, erythema, or fever)
  - If fluctuant, incision, drainage, and appropriate stains and cultures are recommended.
- (4) If infection is suspected, broad-spectrum antibiotic therapy should be instituted and modified as cultures dictate. Dual antibiotic therapy should be instituted if a triggering event is suspected (sinusitis, dental abscess, other) or if the nodule(s) persists, with consideration of a quinolone and macrolide.
- (5) Delayed noninflammatory nodules without suspicion of infection may be treated initially with oral corticosteroids for 1 to 2 weeks, rather than dissolving with hyaluronidase, should the retention of the filler effect be desired. Addition of antibiotics



(doxycycline or minocycline) should be considered for anti-inflammatory and antimicrobial properties.

- (6) Alternatives to a course of oral corticosteroid therapy include intralesional triamcinolone with or without 5-fluorouracil (5-FU), or intralesional hyaluronidase.

### **Evidence and Rationale**

The commissioned systematic review<sup>3</sup> included 6 case series of inflammatory events and 14 of nodules that were treated with hyaluronidase injections (total of approximately 300 patients). The overwhelming majority of these events were of late-onset ( $\geq 1$  month). The reported resolution rates were 80% and 78%; respectively. Other interventions administered in the series included conservative management, saline dressings, probiotics, antibiotics, antihistamines, hydroxychloroquine, oral valacyclovir, ibuprofen, indomethacin, corticosteroids, drainage, and surgery. There were no comparative studies to derive true efficacy estimates for the various interventions. Therefore, this recommendation is based on case reports and adverse events noted in large retrospective analyses<sup>92</sup> and randomized clinical trials<sup>95</sup>; and input of the ASDS task force about how they treat adverse events in their own practice.

Optimal treatment depends on appropriate diagnosis of noninflammatory versus inflammatory nodules<sup>92,96</sup> and whether an infectious process is suspected.<sup>90,96</sup> Severity and associated symptoms of the nodule also play a role in its management. Early nodules (<4 weeks from implantation) due to HA are most likely because of technique or inappropriate product for the area and may be efficiently treated with reassurance or dissolved with hyaluronidase depending on severity. Some HA fillers are more difficult to dissolve and may require increased doses of hyaluronidase for complete resolution.<sup>97,98</sup> Delayed-onset nodules (>4 weeks from implantation) are often likely immune-mediated, but may be infectious.<sup>83,92</sup> It is important to first rule out and/or treat active acute infectious processes, obtain cultures and treat with antibiotics if infection is suspected. Without s/s of active infection (fluctuance, heat, associated adjacent or concomitant systemic infection), oral corticosteroids have proven effective, particularly with Vycross-associated nodules.<sup>92</sup>

Dosing protocols vary, ranging from 1 to 2 weeks of therapy with or without tapering and repeating the course of corticosteroids, should the nodule recur, with an average starting dose of 30 mg of prednisone per day. Intralesional triamcinolone acetonide may be considered if oral steroids are contraindicated or declined. Concomitant treatment with doxycycline or minocycline should be considered as well for antimicrobial and anti-inflammatory effects. In cases resistant to treatment with cortisone and antibiotics, hyaluronidase in appropriate doses depending on the filler may be instituted. Products using Vycross technology prove harder to dissolve, and larger doses may be necessary, with hundreds of units of hyaluronidase needed to dissolve 1 cc of Vycross gels.<sup>98</sup> Biofilms may play a role in resistant cases although a cause and effect role has not been proven.<sup>90</sup> Intralesional 5-FU (50 mg/mL) in combination with triamcinolone may be helpful for

stubborn cases as 5-FU has been well documented to have both antimetabolic and antimicrobial effects.<sup>88</sup>

### **Certainty in Evidence and Strength of Recommendation**

The current recommendation depends on observational studies of low certainty. The panel considered patient's values that emphasize great desire to resolve nodules and other factors such as feasibility and acceptability of the recommended treatments.

### **Implementation Techniques**

Expert consensus is that not all nodules require treatment. Early-onset nodules are often related to placement of the material or injection responses that frequently resolve with time. Some late-onset nodules may resolve spontaneously without treatment and can be followed clinically.<sup>92</sup> Treatment options for noninflammatory delayed nodules include 30 mg of prednisone given by mouth in the morning for 1 to 2 weeks in combination with doxycycline or minocycline. Alternatives include intralesional triamcinolone with or without 5-FU (see implementation section under non-HA and permanent fillers for more information). For unresponsive or recurrent delayed nodules, hyaluronidase is effective in proper doses. Vycross technology may take hundreds of units to dissolve 1 cc of gel. Fluctuant, warm nodules should be approached differently, with the consideration for an infectious etiology that would require incision and drainage, bacterial culture, and antibiotic therapy. Biopsy is rarely needed, because clinical correlation can be sufficient to make the diagnosis but may be useful in resistant cases, especially where prior placement of permanent fillers is suspected.

### **Future Research**

Comparative studies with different management protocols would be invaluable but may be impractical because of the relatively small numbers of cases per institution. Therefore, prospective patient registries and multicenter collaborations are needed. Further understanding etiology of delayed nodules and optimal dosing for corticosteroid therapy and hyaluronidase is needed.

### **Treatment of Nodules Caused From Permanent and Semipermanent Fillers Background**

Nodules and induration are more common with the permanent fillers liquid injectable silicone (LIS) and polymethylmethacrylate (PMMA) (Bellafill, Suneva Medical, San Diego, CA and others outside the US).<sup>90,99–101</sup> They appear years after injection and are usually granulomatous on biopsy. Non FDA-approved hydrogel polymers polyacrylimide (Bio-Alcamid, Polymekon, Brandisi, Italy) and polyacrylamide (Aquamid, Soeburg, Denmark, and others outside the US) are prone to late-appearing abscesses that may be infectious and drainable.<sup>90,102–106</sup> Semipermanent fillers include poly-L-lactic acid (PLLA) (Sculptra,

Restylane fillers; Galderma, Uppsala, Sweden) and calcium hydroxylapatite (CaHa) (Radiesse, Belotero fillers; Merz, Franksville WI), which are not permanent but induce fibroplasia over time. Both may cause nodules that may be granulomatous on biopsy.<sup>107,108</sup> Occasionally, nodules may occur because of overcorrection, excessive fibroplasia, or misplacement of product too superficially or in inappropriate anatomical areas. Unfortunately, in most cases there is no erasing agent to eradicate these fillers, as is possible with hyaluronidase for HA fillers (with the possible exception of sodium thiosulfate for CaHa).<sup>77,78</sup>

## Recommendations

The ASDS task force suggests the following measures to manage nodules caused from permanent and semipermanent fillers (conditional recommendation, low certainty evidence):

- (1) In patients presenting with nodules after skin fillers, identification of the filler responsible for the nodule is important because filler type can affect the choice of treatment. If history is not reliable, we suggest a biopsy or ultrasound.
- (2) In patients with “hot” nodules that are red, tender, edematous, indurated, and warm, antibiotic therapy that covers common skin pathogens (staphylococcus aureus, streptococcal species, p. acnes) may be considered.
- (3) In patients with fluctuant nodules, incision, drainage, and cultures are recommended.
- (4) In patients with “cold” nodules (not red, tender, warm, or fluctuant) caused by LIS or PMMA, intralesional injections of 5-FU mixed with triamcinolone at monthly intervals are recommended. Laser therapies may be considered for those who fail intralesional injections.
- (5) In patients with nodules after hydrogel polymers (Bioalcamid, Aquamid) who are more prone to late-appearing fluctuant abscesses, incision and drainage of the filler, with antibiotics to cover streptococcus viridans in addition to common skin pathogens are recommended.
- (6) In patients with nodules caused from PLLA, watchful waiting is recommended because these nodules usually resolve over months to years without treatment. Injections with triamcinolone with or without 5-FU may be useful for troublesome nodules where watchful waiting is not acceptable.
- (7) Nodules from CaHa usually resolve over months to years without treatment. For troublesome nodules where watchful waiting is not acceptable, intralesional injection of aqueous solutions with vigorous massage, and consideration of sodium thiosulfate are recommended.
- (8) Surgical excision is considered a last resort

## Evidence and Rationale

The commissioned systematic review<sup>3</sup> included 22 non-comparative case series totaling 333 patients who were treated for inflammatory events related to different types of permanent and semipermanent dermal fillers. Resolution of filler-related inflammatory events after receiving an intervention was achieved in 86% of the patients. Most of the cases were late-onset ( $\geq 1$  month). Patients who underwent treatment for early-onset inflammatory events ( $< 1$  month) had a 100% success rate. Interventions used in this series included massage, ice compresses, non steroidal anti inflammatory medications

(NSAIDs), corticosteroids, antibiotics, laser therapy, needle aspiration, incision and drainage, and surgery. Data were inadequate to draw conclusions about the efficacy of different interventions. The review also identified 25 noncomparative case series totaling 684 patients who were treated for nodules related to permanent and semipermanent dermal filler injections. Resolution of nodules after receiving an intervention was achieved in 77% of the patients; most of which were of late-onset nodules ( $\geq 1$  month). Interventions used in this series include massage, NSAIDs, corticosteroids, antibiotics, hydroxychloroquine, laser therapy, needle aspiration, incision and drainage, and surgery. Data were inadequate to draw conclusions about the efficacy of the various interventions.

In patients presenting with nodules after injectable fillers, identification of the filler responsible for the nodule is essential, as the filler type will affect the choice of treatment, especially with non-HA fillers. If history is not reliable, biopsy or ultrasound may offer guidance.<sup>20,109,110</sup>

Most nodules caused by LIS and PMMA appear years after injection. Nodules are usually foreign body granulomas on biopsy and respond to injection with intralesional triamcinolone.<sup>99</sup> There are reports of successfully treating PMMA and other permanent filler nodules with laser.<sup>111,112</sup> Many nodules caused by fillers (permanent or non-permanent) are labeled biofilms. Biofilms are complex colonies of bacteria that adhere to surfaces and are resistant to antibiotics and difficult to culture. Although there is insufficient evidence proving that biofilms are causative of filler nodules, it is prudent to consider antimicrobial therapy. Some protocols recommend 2 weeks of double antibiotic therapy (a macrolide and quinolone),<sup>90</sup> but efficacy data are lacking. There is solid evidence that 5-FU has potent antimicrobial properties, in addition to antimicrobial properties.<sup>88,113</sup> Monthly intralesional injection of lower doses of triamcinolone admixed with 50 mg/cc 5-FU has proven effective for delayed nodules from LIS and may decrease the risk of adverse events associated with higher doses and concentrations of triamcinolone, while adding the antimicrobial properties of 5-FU.<sup>100</sup> However, nodules or induration may reappear over months to years, necessitating reinjection.

Hydrogel polymers consist of over 95% water and a small percentage of the synthetic polymers polyalkylamide (Bio-Alcamid) or polyacrylamide (Aquamid). Both are associated with late-appearing infections, and antimicrobial therapy should be used when treating nodules or abscesses. In 2 publications reporting a total of 19 cases of late-appearing abscesses to Bio-Alcamid, most resolved with incision and drainage, with and without irrigation. Cultures revealed streptococcus species in the majority, particularly streptococcus viridans, which underscores the recommendation to use antibiotics covering streptococcus species in these cases.<sup>102,104</sup> Nondrainable nodules without fluctuance may be treated with broad-spectrum oral antibiotics and intralesional 5-FU and triamcinolone.

Nodules related to PLLA are often granulomatous on biopsy<sup>107,108</sup> and may be treated with intralesional

cortisone with or without 5-FU. Nodules will often spontaneously resolve over months to years.

Nodules related to CaHa also often spontaneously resolve over months to years. Injections of aqueous solutions combined with massage may also help disperse CaHa nodules.<sup>114</sup> Early evidence is promising using intralesional sodium thiosulfate to eradicate CaHa in vivo to resolve nodules, but it requires further study to determine efficacy and safety.<sup>77,78</sup>

For all nodules caused by permanent and semipermanent fillers, excision is a last resort.

### **Certainty in evidence and strength of recommendation**

The current recommendation depends on observational studies of low certainty. The panel considered patient's values that emphasize great desire to resolve nodules and other factors such as feasibility and acceptability of the recommended treatments.

### **Implementation Techniques**

Where indicated as an intralesional treatment, 5-FU is supplied as a 50 mg/cc solution. One long-term study has achieved good results treating LIS nodules with 1 cc of 50 mg/cc 5-FU admixed with 0.1 cc of 40 mg/cc triamcinolone and injected intralesionally into the nodule.<sup>100</sup> Superficial intradermal injections should be avoided to prevent atrophy. It is recommended not to exceed 2 cc's of this mixture during a single treatment to avoid systemic toxicity. Treatments are performed at monthly intervals until optimal resolution is achieved. For all nodules, the ASDS task force suggests excision as a last resort, where other treatment modalities have failed.

### **Future Research**

Future research is needed to define the role of biofilm and immune system triggers in the etiology of nodules caused from permanent and semipermanent fillers, and the role of antimicrobial and immune suppressant therapies. Further research is also needed to elucidate the safety and effectiveness of sodium thiosulfate for CaHA nodules, and to develop more proven treatment protocols.

### **Acknowledgments**

Editorial support was provided to the authors by Diane K Murphy, MBA, and was funded by ASDS.

### **References**

1. Povolotskiy R, Oleck NC, Hatzis CM, Paskhover B. Adverse events associated with aesthetic dermal fillers: a 10-year retrospective study of FDA data. *Am J Cos Surg* 2018;35:143–51.
2. Rayess HM, Svider PF, Hanba C, Patel VS, et al. A cross-sectional analysis of adverse events and litigation for injectable fillers. *JAMA Facial Plast Surg* 2018;20:207–14.
3. Nayfeh T, Shah S, Malindras K, Amin M, et al. A systematic review supporting the American Society for Dermatologic Surgery guidelines on the prevention and treatment of adverse events of injectable fillers. *Dermatol Surg* 2021;47:227–34.
4. Murad MH. Clinical practice guidelines: a primer on development and dissemination. *Mayo Clin Proc* 2017;92:423–33.
5. Kim YS, Choi DY, Gil YC, Hu KS, et al. The anatomical origin and course of the angular artery regarding its clinical implications. *Dermatol Surg* 2014;40:1070–6.
6. Beleznyay K, Carruthers JDA, Humphrey S, Carruthers A, et al. Update on avoiding and treating blindness from fillers: a recent review of the world literature. *Aesthet Surg J* 2019;39:662–74.
7. Goodman GJ, Roberts S, Callan P. Experience and management of intravascular injection with facial fillers: results of a multinational survey of experienced injectors. *Aesthet Plast Surg* 2016;40:549–55.
8. Pavicic T, Webb KL, Frank K, Gotkin RH, et al. Arterial wall penetration forces in needles versus cannulas. *Plast Reconstr Surg* 2019;143:504e–512e.
9. Fitzgerald R, Bertucci V, Sykes JM, Duplechain JK. Adverse reactions to injectable fillers. *Facial Plast Surg* 2016;32:532–55.
10. Tseng FW, Bommareddy K, Frank K, DeLorenzi C, et al. Descriptive analysis of 213 positive blood aspiration cases when injecting facial soft tissue fillers. *Aesthet Surg J*. 2020;sjaa075. doi:10.1093/asj/sjaa075. Epub 2020 Jun 6.
11. Cotozana S, Lachman N. Arteries of the face and their relevance for minimally invasive facial procedures: an anatomical review. *Plast Reconstr Surg*. 2019;143:416–26. Erratum in: *Plast Reconstr Surg*. 2019;143(4):1282–1283.
12. Cho KH, Dalla Pozza E, Toth G, Bassiri Gharb B, et al. Pathophysiology study of filler-induced blindness. *Aesthet Surg J* 2019;39:96–106.
13. Cotozana S, Alfertshofer M, Frank K, Bertucci V, et al. Relationship between vertical glabellar lines and the supratrochlear and supra-orbital arteries. *Aesthet Surg J*. 2020;sjaa138. doi:10.1093/asj/sjaa138. Epub 2020 May 29.
14. Carruthers JDA, Carruthers JA. Appreciation of the vascular anatomy of aesthetic forehead reflation. *Dermatol Surg* 2018;44:52–54.
15. Choi D, Bae J, Youn K, Kim W, et al. Topography of the dorsal nasal artery and its clinical implications for augmentation of the dorsum of the nose. *J Cosmet Dermatol* 2018;17:637–42.
16. Lee W, Kim JS, Oh W, Koh IS, et al. Nasal dorsum augmentation using soft tissue filler injection. *J Cosmet Dermatol* 2019. doi: 10.1111/jocd.13018. Epub 2019 Jun 3.
17. Carruthers J, Humphrey S, Beleznyay K, Carruthers A. A suggested injection zone for soft tissue fillers in the temple. *Dermatol Surg* 2017;43:756–7.
18. Cotozana S, Gaete A, Hernandez CA, Casabona G, et al. The six different injection techniques for the temple relevant for soft tissue filler augmentation procedures—clinical anatomy and danger zones. *J Cosmet Dermatol* 2020;19:1570–9.
19. Cotozana S, Alfertshofer M, Schenck TL, Bertucci V, et al. Anatomy of the superior and inferior labial arteries revised: an ultrasound investigation and implication for lip volumization. *Aesthet Surg J*. 2020;sjaa137. doi: 10.1093/asj/sjaa137. Epub 2020 May 29.
20. Schelke LW, Decates TS, Velthuis PJ. Ultrasound to improve the safety of hyaluronic acid filler treatments. *J Cosmet Dermatol* 2018;17:1019–24.
21. Park KH, Kim YK, Woo SJ, Kang SW, et al. Iatrogenic occlusion of the ophthalmic artery after cosmetic facial filler injections: a national survey by the Korean Retina Society. *JAMA Ophthalmol* 2014;132:714–23.
22. Chen Y, Wang W, Li J, Yu Y, et al. Fundus artery occlusion caused by cosmetic facial injections. *Chin Med J (Engl)* 2014;127:1434–7.
23. Beleznyay K, Carruthers JD, Humphrey S, Jones D. Avoiding and treating blindness from fillers: a review of the world literature. *Dermatol Surg* 2015;41:1097–117.
24. Sorensen EP, Council ML. Update in soft-tissue filler-associated blindness. *Dermatol Surg* 2020;46:671–7.
25. Chatrath V, Banerjee PS, Goodman GJ, Rahman E. Soft-tissue filler-associated blindness: a systematic review of case reports and case series. *Plast Reconstr Surg Glob Open* 2019;7:e2173.
26. Lee W, Koh IS, Oh W, Yang EJ. Ocular complications of soft tissue filler injections: a review of literature. *J Cosmet Dermatol* 2020;19:772–81.
27. Zhang LX, Lai LY, Zhou GW, Liang LM, et al. Evaluation of intraarterial thrombolysis in treatment of cosmetic facial filler-related ophthalmic artery occlusion. *Plast Reconstr Surg* 2020;145:42e–50e.

28. International Society of Aesthetic Plastic Surgery. *ISAPS Global Statistics*. Available from: <https://www.isaps.org/medical-professionals/isaps-global-statistics>. Accessed March 17, 2020.
29. Abtahi-Naeini B, Pourazizi M, Saffaei A. Systematic review of soft-tissue filler-associated blindness: a methodologic concern beyond duplicated cases. *Plast Reconstr Surg Glob Open* 2019;7:e2380.
30. Carruthers JD, Fagien S, Rohrich RJ, Weinkle S, et al. Blindness caused by cosmetic filler injection: a review of cause and therapy. *Plast Reconstr Surg* 2014;134:1197–201.
31. Hayreh SS, Zimmerman MB, Kimura A, Sanon A. Central retinal artery occlusion. Retinal survival time. *Exp Eye Res* 2004;78:723–36.
32. Tobalem S, Schutz JS, Chronopoulos A. Central retinal artery occlusion—rethinking retinal survival time. *BMC Ophthalmol* 2018;18:101.
33. Joganathan V, Shah-Desai S. Awareness of management of hyaluronic acid induced visual loss: a British National Survey. *Eye (Lond)*. 2020;34:2280–2283.
34. Kapoor KM, Kapoor P, Heydenrych I, Bertossi D. Vision loss associated with hyaluronic acid fillers: a systematic review of literature. *Aesthet Plast Surg* 2020;44:929–44.
35. Kim A, Kim SH, Kim HJ, Yang HK, et al. Ophthalmoplegia as a complication of cosmetic facial filler injection. *Acta Ophthalmol* 2016;94:e377–e379.
36. Yang HK, Lee Y, Woo SJ, Park KH, et al. Natural course of ophthalmoplegia after iatrogenic ophthalmic artery occlusion caused by cosmetic filler injections. *Plast Reconstr Surg* 2019;144:28e–34e.
37. Zhang L, Pan L, Xu H, Yan S, et al. Clinical observations and the anatomical basis of blindness after facial hyaluronic acid injection. *Aesthet Plast Surg* 2019;43:1054–60.
38. Kim YK, Jung C, Woo SJ, Park KH. Cerebral angiographic findings of cosmetic facial filler-related ophthalmic and retinal artery occlusion. *J Korean Med Sci* 2015;30:1847–55.
39. Thanasarnakorn W, Cotofana S, Rudolph C, Kraissak P, et al. Severe vision loss caused by cosmetic filler augmentation: case series with review of cause and therapy. *J Cosmet Dermatol* 2018;17:712–8.
40. Wibowo A, Kapoor KM, Philipp-Dormston WG. Reversal of post-filler vision loss and skin ischaemia with high-dose pulsed hyaluronidase injections. *Aesthet Plast Surg* 2019;43:1337–44.
41. Chesnut C. Restoration of visual loss with retrobulbar hyaluronidase injection after hyaluronic acid filler. *Dermatol Surg* 2018;44:435–7.
42. Goodman GJ, Clague MD. A rethink on hyaluronidase injection, intraarterial injection, and blindness: is there another option for treatment of retinal artery embolism caused by intraarterial injection of hyaluronic acid? *Dermatol Surg* 2016;42:547–9.
43. Lee JL, Kang SJ, Sun H. Skin necrosis with oculomotor nerve palsy due to a hyaluronic acid filler injection [published correction appears in *Arch Plast Surg*. 2017 Nov;44(6):575–576]. *Arch Plast Surg* 2017;44:340–3.
44. Sharudin SN, Ismail MF, Mohamad NF, Vasudevan SK. Complete recovery of filler-induced visual loss following subcutaneous hyaluronidase injection. *Neuroophthalmology* 2018;43:102–6.
45. Surek CC, Said SA, Perry JD, Zins JE. Retrobulbar injection for hyaluronic acid gel filler-induced blindness: a review of efficacy and technique. *Aesthet Plast Surg* 2019;43:1034–40.
46. Paap MK, Milman T, Ugradar S, Goldberg R, et al. Examining the role of retrobulbar hyaluronidase in reversing filler-induced blindness: a systematic review. *Ophthalmic Plast Reconstr Surg* 2020;36:231–8.
47. Chen YC, Wu HM, Chen SJ, Lee HJ, et al. Intra-Arterial thrombolytic therapy is not a therapeutic option for filler-related central retinal artery occlusion [published correction appears in *Facial Plast Surg*. *Facial Plast Surg* 2018;34:325–9.
48. Peter S, Mennel S. Retinal branch artery occlusion following injection of hyaluronic acid (Restylane). *Clin Exp Ophthalmol* 2006;34:363–4.
49. Chen W, Wu L, Jian XL, Zhang B, et al. Retinal branch artery embolization following hyaluronic acid injection: a case report. *Aesthet Surg J* 2016;36:NP219–NP224.
50. Landau M. Hyaluronidase Caveats in treating filler complications. *Derm Surg* 2020;41:S347–S353.
51. Rzany B, DeLorenzi C. Understanding, avoiding, and managing severe filler complications. *Plast Reconstr Surg* 2015;136(5 suppl):196S–203S.
52. McCann M. Intravenous hyaluronidase for visual loss secondary to filler injection: a novel therapeutic approach. *J Clin Aesthet Dermatol* 2019;12:25–7.
53. Lee W, Oh W, Ko HS, Lee SY, et al. Effectiveness of retrobulbar hyaluronidase injection in an iatrogenic blindness rabbit model using hyaluronic acid filler injection [published correction appears in *Plast Reconstr Surg*. 2020 Jan;145(1):289]. *Plast Reconstr Surg* 2019;144:137–43.
54. Chiang C, Zhou S, Chen C, Ho DS, et al. Intravenous hyaluronidase with urokinase as treatment for rabbit retinal artery hyaluronic acid embolism. *Plast Reconstr Surg* 2016;138:1221–9.
55. Cohen JL. Understanding, avoiding, and managing dermal filler complications. *Dermatol Surg* 2008;34(suppl 1):S92–9.
56. Alam M, Tung R. Injection technique in neurotoxins and fillers: indications, products, and outcomes. *J Am Acad Dermatol* 2018;79:423–35.
57. Alam M, Tung R. Injection technique in neurotoxins and fillers: planning and basic technique. *J Am Acad Dermatol* 2018;79:407–19.
58. McGuire LK, Hale EK, Godwin LS. Post-filler vascular occlusion: a cautionary tale and emphasis for early intervention. *J Drugs Dermatol* 2013;12:1181–3.
59. Alam M, Kakar R, Nodzenski M, Ibrahim O, et al. Multicenter prospective cohort study of the incidence of adverse events associated with cosmetic dermatologic procedures: lasers, energy devices, and injectable neurotoxins and fillers. *JAMA Dermatol* 2015;151:271–7.
60. Casabona G. Blood aspiration test for cosmetic fillers to prevent accidental intravascular injection in the face. *Dermatol Surg* 2015;41:841–7.
61. DeLorenzi C. Complications of injectable fillers, part 2: vascular complications. *Aesthet Surg J* 2014;34:584–600.
62. Glaich AS, Cohen JL, Goldberg LH. Injection necrosis of the glabella: protocol for prevention and treatment after use of dermal fillers. *Dermatol Surg* 2006;32:276–81.
63. Lee W, Oh W, Oh SM, Yang EJ. Comparative effectiveness of different interventions of perivascular hyaluronidase. *Plast Reconstr Surg* 2020;145:957–64.
64. Rauso R, Zerbinati N, Franco R, Chirico F, et al. Cross-linked hyaluronic acid filler hydrolysis with hyaluronidase: different settings to reproduce different clinical scenarios. *Dermatol Ther* 2020;33:e13269.
65. Li J, Xu Y, Wang Y, Hsu Y, et al. The role of hyaluronidase for the skin necrosis caused by hyaluronic acid injection-induced embolism: a rabbit auricular model study. *Aesthet Plast Surg* 2019;43:1362–70.
66. Ciancio F, Tarico MS, Giudice G, Perrotta RE. Early hyaluronidase use in preventing skin necrosis after treatment with dermal fillers: report of two cases. *F1000Res* 2018;7:1388.
67. Fang M, Rahman E, Kapoor KM. Managing complications of submental artery involvement after hyaluronic acid filler injection in chin region. *Plast Reconstr Surg Glob Open* 2018;6:e1789.
68. Juhász ML, Marmur ES. Temporal fossa defects: techniques for injecting hyaluronic acid filler and complications after hyaluronic acid filler injection. *J Cosmet Dermatol* 2015;14:254–9.
69. Cohen JL, Biesman BS, Dayan SH, DeLorenzi C, et al. Treatment of hyaluronic acid filler-induced impending necrosis with hyaluronidase: consensus recommendations. *Aesthet Surg J* 2015;35:844–9.
70. Beleznyay K, Humphrey S, Carruthers JD, Carruthers A. Vascular compromise from soft tissue augmentation: experience with 12 cases and recommendations for optimal outcomes. *J Clin Aesthet Dermatol* 2014;7:37–43.
71. Alam M, Hughart R, Geisler A, Paghдал K, et al. Effectiveness of low doses of hyaluronidase to remove hyaluronic acid filler nodules: a randomized clinical trial. *JAMA Dermatol* 2018;154:765–72.
72. Alam M, Dover JS. Management of complications and sequelae with temporary injectable fillers. *Plast Reconstr Surg* 2007;120(6 suppl):98S–105S.

73. Chauhan A, Singh S. Management of delayed skin necrosis following hyaluronic acid filler injection using pulsed hyaluronidase. *J Cutan Aesthet Surg* 2019;32:183–6.
74. Hwang CJ, Morgan PV, Pimentel A, Sayre JW, et al. Rethinking the role of nitroglycerin ointment in ischemic vascular filler complications: an animal model with ICG imaging. *Ophthalmic Plast Reconstr Surg* 2016;32:118–22.
75. Kleydman K, Cohen JL, Marmur E. Nitroglycerin: a review of its use in the treatment of vascular occlusion after soft tissue augmentation. *Dermatol Surg* 2012;38:1889–97.
76. Carley SK, Kraus CN, Cohen JL. Nitroglycerin, or not, when treating impending filler necrosis. *Dermatol Surg* 2020;46:31–40.
77. Robinson DM. In vitro analysis of the degradation of calcium hydroxylapatite dermal filler: a proof-of-concept study. *Dermatol Surg* 2018;44:S5–S9.
78. Rullan PP, Olson R, Lee KC. The use of intralesional sodium thiosulfate to dissolve facial nodules from calcium hydroxylapatite. *Dermatol Surg* 2020;46:1366–8.
79. Cassiano D, Miyuki Iida T, Lúcia Recio A, Yarak S. Delayed skin necrosis following hyaluronic acid filler injection: a case report. *Cosmet Dermatol* 2020;19:582–4.
80. Hong JY, Seok J, Ahn GR, Jang YJ, et al. Impending skin necrosis after dermal filler injection: a golden time for first-aid intervention. *Dermatol Ther* 2017;30. doi: 10.1111/dth.12440.
81. Uittenbogaard D, Lansdorp CA, Bauland CG, Boonstra O. Hyperbaric oxygen therapy for dermal ischemia after dermal filler injection with calcium hydroxylapatite: a case report. *Undersea Hyperb Med* 2019;46:207–10.
82. Zeichner JA, Cohen JL. Use of blunt tipped cannulas for soft tissue fillers. *J Drugs Dermatol* 2012;11:70–2.
83. Jones D, Bank D. Five-year postmarket safety experience with the optimal balance technology of hyaluronic acid filler. *Dermatol Surg* 2020;46:145–7.
84. Fabi SG, Champagne JP, Nettare KD, Maas CS, et al. Efficacy and safety of and patient satisfaction with injectable hyaluronic acid with 0.3% lidocaine hydrochloride for the treatment of superficial perioral lines or superficial lateral canthal lines. *Dermatol Surg* 2013;39:1613–20.
85. Beleznyak K, Carruthers JD, Carruthers A, Mummert ME, et al. Delayed-onset nodules secondary to a smooth cohesive 20 mg/mL hyaluronic acid filler: cause and management. *Dermatol Surg* 2015;41:929–39.
86. Artzi O, Loizides C, Verner I, Landau M. Resistant and recurrent late reaction to hyaluronic acid-based gel. *Dermatol Surg* 2016;42:31–7.
87. Sadehpour M, Quatrano NA, Bonati LM, Arndt KA, et al. Delayed-onset nodules to differentially crosslinked hyaluronic acids: comparative incidence and risk assessment. *Dermatol Surg* 2019;45:1085–94.
88. Beer K, Avelar R. Relationship between delayed reactions to dermal fillers and biofilms: facts and considerations. *Dermatol Surg* 2014;40:1175–9.
89. Saththianathan M, Johani K, Taylor A, Hu H, et al. The role of bacterial biofilm in adverse soft tissue filler reactions: a combined laboratory and clinical study. *Plast Reconstr Surg* 2017;139:613–21.
90. Ibrahim O, Overman J, Arndt KA, Dover J. Filler nodules: inflammatory or infectious? a review of biofilms and their implications on clinical practice. *Dermatol Surg* 2018;44:53–60.
91. Turkmani MG, De Boule K, Philipp-Dormston WG. Delayed hypersensitivity reaction to hyaluronic acid dermal filler following influenza-like illness. *Clin Cosmet Investig Dermatol* 2019;12:277–83.
92. Humphrey S, Jones DH, Carruthers JD, Carruthers A, et al. Retrospective review of delayed adverse events secondary to treatment with a smooth, cohesive 20-mg/mL hyaluronic acid filler in 4500 patients. *J Am Acad Dermatol* 2020;83:86–95.
93. Alam M, Cohen JL, Petersen B, Schlessinger DI, et al. Association of different surgical sterile prep solutions with infection risk after cutaneous surgery of the head and neck. *JAMA Dermatol* 2017;153:830–1.
94. Dumville JC, McFarlane E, Edwards P, Lipp A, et al. Preoperative skin antiseptics for preventing surgical wound infections after clean surgery. *Cochrane Database Syst Rev* 2015;2015:CD003949.
95. Jones D, Murphy D. Volumizing hyaluronic acid filler for midface volume deficit: 2 year results from a pivotal single-blind randomized controlled study. *Dermatol Surg* 2013;39:1602–11.
96. Bitterman-Deutsch O, Kogan L, Nasser F. Delayed immune mediated adverse effects to hyaluronic Acid fillers: report of five cases and review of the literature. *Dermatol Rep* 2015;7:5851.
97. Jones D, Tezel A, Borrell M. In vitro resistance to degradation of hyaluronic acid dermal fillers by ovine testicular hyaluronidase. *Dermatol Surg* 2010;36:804–9.
98. Shumate GT, Chopra R, Jones D, Messina DJ, et al. In vivo degradation of crosslinked hyaluronic acid fillers by exogenous hyaluronidases. *Dermatol Surg* 2018;44:1075–83.
99. Gelfer A, Carruthers A, Carruthers J, Jang F, et al. The natural history of polymethylmethacrylate microspheres granulomas. *Dermatol Surg* 2007;33:614–20.
100. Jones D, Carruthers A, Brody HJ, Black JM, et al. Ten-year and beyond follow-up after treatment with highly purified liquid-injectable silicone for HIV-associated facial lipoatrophy: a report of 164 patients. *Dermatol Surg* 2019;45:941–8.
101. Lehman A, Pilcher B, Roberts WE, Schlesinger TE, et al. Postmarket experience of polymethylmethacrylate-collagen gel dermal filler. *Dermatol Surg* 2020;46:1086–91.
102. Jones DH, Carruthers A, Fitzgerald R, Sarantopoulos GP, et al. Late-appearing abscesses after injections of nonabsorbable hydrogel polymer for HIV-associated facial lipoatrophy. *Dermatol Surg* 2007;33(Suppl 2):S193–S198.
103. Daines SM, Williams EF. Complications associated with injectable soft-tissue fillers: a 5-year retrospective review. *JAMA Facial Plast Surg* 2013;15:226–31.
104. Goldan O, Georgiou I, Grabov-Nardini G, Regev E, et al. Early and late complications after a nonabsorbable hydrogel polymer injection: a series of 14 patients and novel management. *Dermatol Surg* 2007;33(Suppl 2):S199–S206.
105. Negrodo E, Puig J, Ornelas A, Echeverría P, et al. Ten-year safety with polyacrylamide gel used to correct facial lipoatrophy in HIV-infected patients. *AIDS Res Hum Retroviruses* 2015;31:817–21.
106. Shen H, Lv Y, Xu JH, Hong XY, et al. Complications after polyacrylamide hydrogel injection for facial soft-tissue augmentation in China: twenty-four cases and their surgical management. *Plast Reconstr Surg* 2012;130:340e–348e.
107. Wildemore JK, Jones DH. Persistent granulomatous inflammatory response induced by injectable poly-L-lactic acid for HIV lipoatrophy. *Dermatol Surg* 2006;32:1407–9.
108. Beer K. Clinicopathologic correlation of delayed-onset periorbital poly-L-lactic acid nodules. *Dermatol Surg* 2009;35:399–402.
109. Schelke LW, Van Den Elzen HJ, Erkamp PPM, Neumann HAM. Use of ultrasound to provide overall information on facial fillers and surrounding tissue. *Dermatol Surg* 2010;36:1843–51.
110. Wortsman X. Identification and complications of cosmetic fillers. *J Ultrasound Med* 2015;34:1163–72.
111. Cassuto D, Marangoni O, De Santis G, Christensen L. Advanced laser techniques for filler-induced complications. *Dermatol Surg* 2009;35(Suppl 2):1689–95.
112. Rivers JK, Labonté-Truong N, Richer V. Adjuvant use of a 1,064 nm neodymium-doped yttrium aluminum garnet laser for the management of refractory late-onset nodules related to polymethylmethacrylate fillers [published online ahead of print]. *Dermatol Surg* 2020. doi:10.1097/DSS.0000000000002301.
113. Jones D. Treatment of delayed reactions to dermal fillers. *Dermatol Surg* 2014;40:1180.
114. Voigts R, DeVore DP, Grazer JM. Dispersion of calcium hydroxylapatite accumulations in the skin: animal studies and clinical practices. *Dermatol Surg* 2010;36:798–803.